

Cavitation adipocytolysis with a new micro-gelatinous injectable for subcutaneous adipose tissue volume reduction: *ex-vivo* histological findings

Giovanni Salti MD¹ and Pasquale Motolese MD²

¹Istituto Medilight – Florence Italy

²Professor FORMEST University of Ferrara Italy

ABSTRACT

The purpose of this study was to investigate the effects on biopsies of adipose tissue obtained from an abdominoplasty with a new injectable adipocytolytic solution (Aqualyx®), which does not contain phosphatidylcholine, combined with external medium frequency ultrasound. Biopsies taken from adipose tissue were infiltrated with Aqualyx® alone and with Aqualyx® combined with a subsequent application of external medium frequency ultrasound. The biopsies were fixed in formalin and embedded in paraffin. Sections were stained with hematoxylin and eosin and then analyzed. Untreated adipose tissue and adipose tissue treated only with intralipotherapy needle insertion, served as controls. Sections were analyzed using light microscopy. Compared to the adipose tissues not treated by infiltration nor by infiltration plus external ultrasound distinct damages of the cellular structure of the adipocytes could be seen. The destruction was especially visible in the sections

treated with Aqualyx® and external ultrasound (cavitation adipocytolyses). In comparison, the adipose tissue of the controls was mostly intact. In conclusion our results indicate that cavitation adipocytolyses using Aqualyx® combined with external medium frequency ultrasound is effective for the lysis of adipocytes.

KEYWORDS: Localized adiposity, Adipocytolysis, Aqualyx, intralipotherapy

Eur. J. Aesth. Medicine and Dermatology. 2012;2;(2):94-97

INTRODUCTION

The use of external ultrasound after adipose tissue has been infiltrated with saline solution to produce the phe-

nomenon of intra-tissue cavitation was introduced in Italy about 20 years ago. This combination was used to reduce deposits of

CORRESPONDENCE

Giovanni Salti MD
Istituto Medilight
Via Maragliano 29L - 50144 Firenze
glosal@fol.it

DISCLOSURES

Dr. Giovanni Salti has no relevant conflicts of interest to disclose. Dr. Pasquale Motolese is the creator of the formula of Aqualyx® and he earns royalties from the worldwide distribution.

subcutaneous fat in body areas where there is an excess of adipose tissue (localized adiposity). The Method, called "Ultrasonic Hydrolipoclasia"⁽¹⁾ despite opening the way to new possible applications in aesthetic medicine, never proved to be particularly effective. Despite the fact that the initial rationale was unclear, the use of Lipostabil introduced more recently^(2,3), opened the way to a new treatment protocol for localized adiposities with a certain effectiveness.

The great interest and widespread use of localized injections of Lipostabil have stimulated research towards a better understanding of the underlying mechanisms of action of these solutions in the tissues, identifying sodium deoxycholate as the active ingredient, a molecule with a deterging action^(4,5) and excluding the initial hypothesis of a lipolytic action of the phosphatidylcholine⁽⁶⁾.

These acquisitions have subsequently led to the formulation of new solutions where only the sodium deoxycholate in aqueous solu-

tions is a high risk for skin necrosis (data not published) (fig 1 and 2), given the strong ag-

gressiveness of the molecule.

In relation to the mode of action of these injectable solutions, a protocol for the selective infiltration of adipose tissue called intralipotherapy⁽⁷⁾ was proposed, completely different from mesotherapy (intradermotherapy) that is frequently indicated as a mode of infiltration. Aqualyx® is a complex micro-gelatinous injectable solution that doesn't contain phospholipids, it is formulated to predispose the adipocytes to lysis amplifying the effects of external ultrasound^(8, 9).

MATERIALS AND METHODS

Four samples of adipose tissue were obtained from an abdominoplasty in a 35 year old female subject. All the samples were sized in equal form and measure and composed of adipose tissue, dermis and epidermis (fig. 3). Two of the samples were infiltrated with 5 ml of Aqualyx® with a 24 Gauge intralipotherapy needle (Lipoinject needle® – Marllor Int. Italy)

in proximity to the free margin of the adipose tissue at a precise depth that will permit tak-

FIGURE 1. Skin inflammatory reaction of the upper arm with several ulcerations after infiltration of aqueous solution of sodium deoxycholate in an unknown concentration (Brazil)

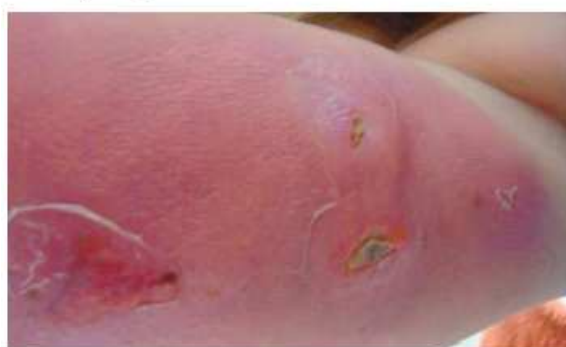

FIGURE 2. Cutaneous necrosis of the thigh after infiltration of sodium deoxycholate in aqueous solution in an unknown concentration (Poland)

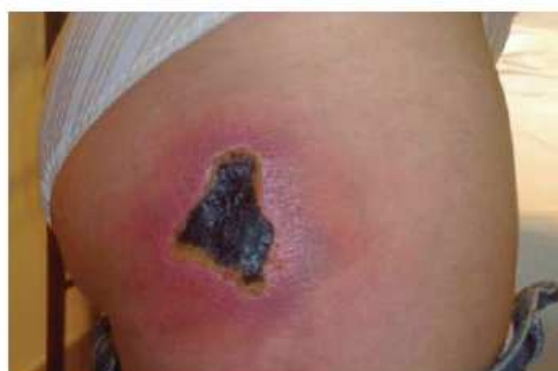

FIGURE 3. Samples of abdominal adipose tissue obtained from abdominoplasty.



ing a precise biopsy.

The third sample was infiltrated with saline solution, while the fourth sample was ex-

posed only to the trauma of the needle.

One of the 2 samples infiltrated with Aqualyx® was later subjected to external medium frequency (516-918 kHz - Sonolyx®, Marllor int. Italy) ultrasound for 10 minutes with the transducer applied at the cutaneous margin. From each sample, multiple biopsies were taken 5 mm from the infiltration site.

The tissue removed was conserved in formaldehyde, fixed in paraffin and stained with hematoxylin and eosin and subjected to a blind pathological anatomic evaluation.

RESULTS

The histological aspects observed in the biopsies taken from the four samples are shown in figures 4A, B, C, D.

The samples infiltrate with saline solution and exposed to multi-traumatic needle insertion (fig. 4A, B), show normal adipose tissue with preservation of the lobular structure. The sample that underwent only infiltration with Aqualyx® shows cellular swelling

with a “split rail” cellular membrane lipidic bilayer separation (fig. 4C). The sample that underwent infiltration with Aqualyx® and was then exposed to external medium frequency ultrasound, in addition to the aspects that were previously described showed homogenised cytoplasm content with alteration of the lobular structure and widespread areas of cellular destruction were noted (fig. 4D).

CONCLUSIONS

Cavitation adipocytolysis is a nonsurgical

FIGURE 4A. Sample infiltrated with 10 cc of saline solution: Normal adipose tissue with preserved lobular structure

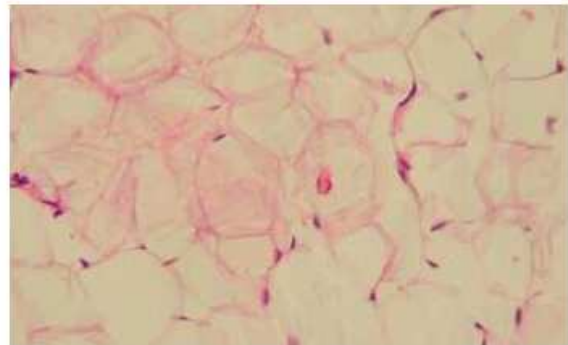


FIGURE 4B. Sample exposed to multiple needle trauma: Normal adipose tissue with preserved lobular structure

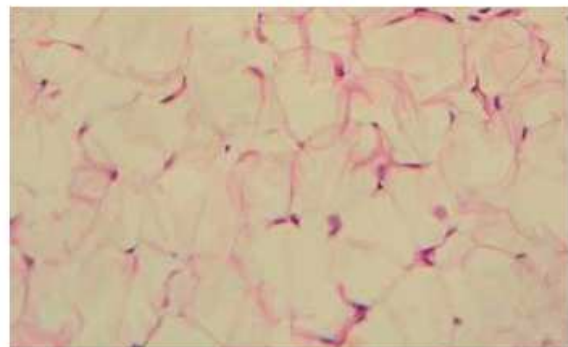


FIGURE 4C. Sample infiltrated with Aqualyx®: swollen adipocytes and "split rail" separation of the cellular membrane lipidic bilayer

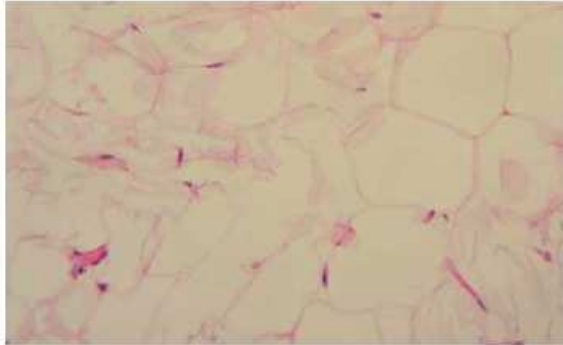
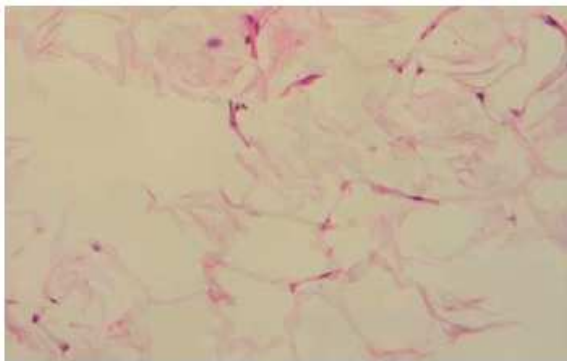


FIGURE 4D. Sample infiltrated with Aqualyx® and subsequently exposed to external ultrasound: swollen adipocytes and "split rail" separation of the cellular membrane lipidic bilayer, homogenised cytoplasm content and widespread area of cellular destruction.



protocol developed for reducing the volumetric excess of localized adipose areas that produce alterations of the body contour in relation to modern rules of aesthetics.

The protocol provides for the synergistic association of an injectable specifically formulated solution and the application of external ultrasound in order to obtain a more selective adipocytolysis.

The histological evidence from human adipose tissue obtained from an abdomino-

plasty showed evidence of lytic action of the adipocytes as well as the adipose lobules as a result of the combination of the two protocols.

Clinical studies awaiting publication, which demonstrate the effectiveness and safety, are carried out on an outpatient basis in aesthetic medicine.

REFERENCES

1. Herreros FO, Velho PE, De Moraes AM, Cintra ML. Cutaneous atypical mycobacteriosis after ultrasound hydrolipolysis treatment. *Dermatol Surg.* 2009 Jan;35(1):158-60. Epub 2008 Dec 6.
2. Rittes PG. The use of phosphatidylcholine for correction of lower lid bulging due to prominent fat pads. *Dermatol Surg.* 2001 Apr;27(4):391-2.
3. Hexsel D, Serra M, Mazzuco R, Dal'Forno T,

Zechmeister D. Phosphatidylcholine in the treatment of localized fat. *J Drugs Dermatol.* 2003 Oct;2(5):511-8.

4. Salti G, Ghersetich I, Tantussi F, Bovani B, Lotti T. Phosphatidylcholine and sodium deoxycholate in the treatment of localized fat: a double-blind, randomized study *Dermatol Surg.* 2008 Jan;34(1):60-6; discussion 66. Epub 2007 Dec 5.
5. Rotunda AM, Suzuki H, Moy RL, Kolodney MS. Detergent effects of sodium deoxycholate are a major feature of an injectable phosphatidylcholine formulation used for localized fat dissolution. *Dermatol Surg.* 2004 Jul;30(7):1001-8.
6. Motolese P. Phospholipids do not have lipolytic activity. A critical review. *J Cosmet Laser Ther.* 2008 Jun;10(2):114-8. Review.
7. Motolese P. Intralipotherapy: a rational infiltrative approach in treatment of localized fat using adipocytolytic injectable solutions. *Marllor International, data on file. Italy.*
8. Pinto H, Melamed G, Fioravanti L. Intralipotherapy Patient Satisfaction Evaluation Study (IPSES). *Eur. J. Aesth. Medicine and Dermatology.* 2012;2;(1):29-34
9. Raoso R. Non surgical reduction of buffalo hump deformity. Case report and literature review. *Eur. J. Aesth. Medicine and Dermatology.* 2011;1;(1):29-34